

CASE REPORT

A Rare Occurrence of Ewing's Sarcoma Presenting as Breast Mass: A Case Report and Literature Review

Ritu Thakur¹, Ravi Venugopal¹, Jyoti Sharma^{1*}, Adarsh Barwad²

¹Department of Surgical Oncology, Institute Rotary Cancer Hospital, All India Institute of Medical Sciences, New Delhi, India

²Department of Pathology, All India Institute of Medical Sciences, New Delhi, India

Abstract: Ewing's sarcoma (EWS) typically involves the bony structures in adolescents and young adults. Extraskelatal sarcoma is a rare, aggressive, and malignant soft-tissue tumor with high recurrence rate. EWS of the breast is a rare entity with <1% cases reported in literature. A 55-year-old lady who complained of the gradual onset painless breast lump lasting for 1 year was referred to our institute in August 2021. Diagnostic ultrasound of bilateral breast identified a cystic lesion measuring 1.8 × 1.5 cm in lower inner quadrant of right breast. Diagnostic excisional biopsy of the right breast lump, which was conducted outside of the institute, showed malignant small round cell tumor. Post-excisional biopsy whole body 18-fluoro-deoxy-glucose positron emission tomography showed no residual uptake with no evidence of metastatic disease elsewhere. Immunohistochemistry work revealed positive expression of NKX2.2 and MIC2, which is consistent with the histopathological feature of EWS. Fluorescent *in situ* hybridization showed *EWSR1* rearrangement, which is consistent with the diagnosis of EWS. The patient underwent a wide local excision of the right breast, followed by adjuvant chemotherapy consisting of 18 weekly vincristine/adriamycin D/cyclophosphamide regimen (vincristine, total dose of 2 mg; adriamycin D 100 mg; and cyclophosphamide 1.6 g). The patient was disease free after follow-up of 1 year. The rarity of primary breast EWS poses a diagnostic dilemma and hence the treatment. Local control with systemic therapy is the cornerstone of the treatment, in which breast conservation surgery is equivalent to mastectomy in patient with a good/average breast volume.

Keywords: Ewing's sarcoma; Breast cancer; Breast conservation surgery; Peripheral primitive neuroectodermal tumor

Received: October 22, 2023

Accepted: February 9, 2023

Published Online: March 3, 2023

***CORRESPONDING AUTHOR**

Jyoti Sharma

E-mail: drjyoti27@yahoo.co.in

CITATION

Thakur R, Venugopal R, Sharma J, *et al.*, 2022, A Rare Occurrence of Ewing's Sarcoma Presenting as Breast Mass: A Case Report and Literature Review. *Cancer Plus*, 4(3):1-5.
DOI: [10.18063/cp.v4i3.385](https://doi.org/10.18063/cp.v4i3.385)

Copyright: © 2023

Thakur, *et al.* This is an Open Access article distributed under the terms of the Creative Commons Attribution-NonCommercial 4.0 International License (<http://creativecommons.org/licenses/by-nc/4.0/>), permitting all noncommercial use, distribution, and reproduction in any medium, provided the original work is properly cited.

1. Background

Ewing's sarcoma (EWS) or peripheral primitive neuroectodermal tumors (PNETs) are rare, malignant, and small blue round cell tumor belonging to the Ewing's family of tumors characterized by the presence of translocation (11;22)(9q24;q12) and immunohistochemistry positivity for CD99^[1]. EWS typically involves the bony structures in adolescents and young adults, primarily in males. EWS family of tumors includes extraosseous EWS, PNET, malignant small cell tumors of the thoracopulmonary region (Askin tumor), and atypical EWS. Extraskelatal sarcoma is a rare, aggressive, and malignant soft-tissue tumor with high recurrence rate. Patients typically present with localized pain or swelling of a duration of a few weeks or months. Primary PNETs mainly affect the truncal and axial soft tissue, including chest wall, extremities, and paravertebral region. More than 85% of EWS cases are characterized by the presence of the typical translocation t(11;22)(q24;q12).

Immunophenotyping further establishes the diagnosis of EWS/PNET, which shows positivity for vimentin, Flt-1, and CD99 (MIC2) (1). Multi-modality treatment including local control with R0 resection followed by adjuvant systemic treatment is advised. EWS of the breast is a rare entity with <1% cases reported in the literature^[2]. To the best of our knowledge, only 16 cases of extraskeletal EWS have been reported in the literature worldwide.

2. Case presentation

A 55-year-old lady who complained of gradual onset painless breast lump lasting for 1 year was referred to our institute in August 2021. Diagnostic ultrasound of bilateral breast identified a cystic lesion measuring 1.8 × 1.5 cm in the lower inner quadrant of the right breast. Diagnostic excisional biopsy of the right breast lump, which was conducted outside of the institute, showed malignant small round cell tumor, but details about margins were not available. Microscopic review suggested that it was malignant round cell tumor with open chromatin with inconspicuous nucleoli. Mitosis was >10/10 hpf. Tumor cell showed focal positivity for CD99, synaptophysin, S100, BCL2 FL1, and Ki-67 (30 – 35%).

Blocks review suggested a malignant round cell tumor with undifferentiated cells with high nuclear-cytoplasmic (NC) ratio, coarse chromatin, and scanty cytoplasm (Figure 1). Immunohistochemistry works showed positive NKX2 expression with diffuse nuclear positivity and positivity for MIC2, which are consistent with histopathological features of EWS (Figure 2). Fluorescent *in situ* hybridization (FISH) was performed using dual-color break-apart probes for *EWSR1* gene showing break-apart signals to reveal *EWSR1* rearrangement, which is consistent with the diagnosis of EWS (Figure 3). Post-excisional biopsy whole body 18-fluoro-deoxy-glucose

positron emission tomography showed no residual uptake with no evidence of metastatic disease elsewhere (Figure 4). Post-excisional mammogram showed normal scan with no architectural distortion or mass lesion (Figure 5).

Treatment plan for this case was breast conservation surgery (wide local excision) followed by adjuvant therapy in view of unknown margin status. The patient underwent a wide local excision of the right breast (Figure 6) followed by adjuvant chemotherapy consisting of 18 weekly vincristine/adriamycin D/cyclophosphamide (VAC) regimen (vincristine, total dose of 2 mg; adriamycin D 100 mg; and cyclophosphamide 1.6 g).

3. Discussion

EWS or PNET belongs to a group of rare malignant neoplasm with blue round cell morphology commonly occurring in

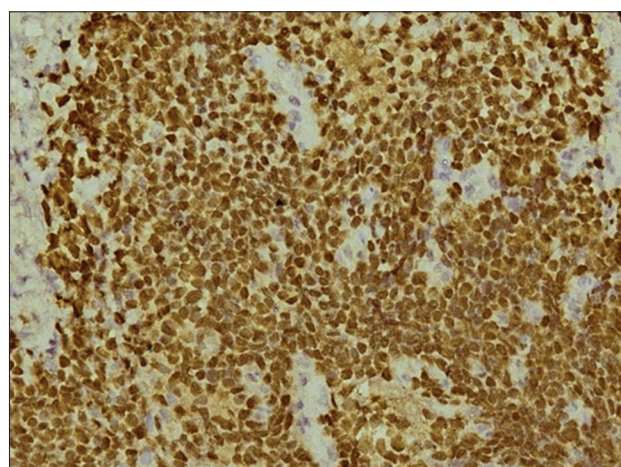


Figure 2. Immunohistochemistry for NKX2.2 showing diffuse nuclear positivity. Antibody from clone SPM 564 (NeoBiotechnologies, Union City, CA, United States) in a dilution of 1:300 was used (×10 magnification).

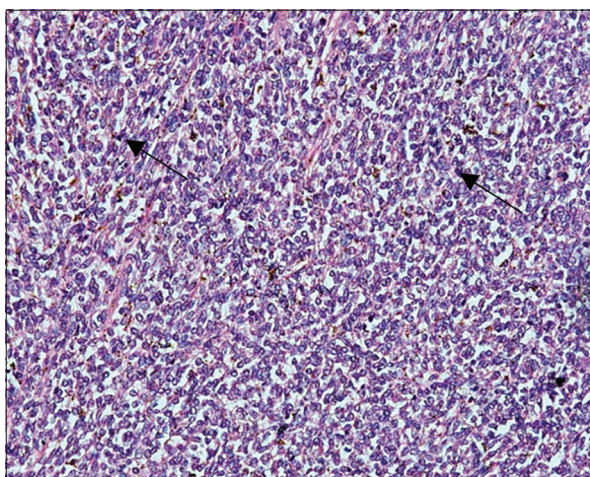


Figure 1. Histology showing a malignant round cell tumor with undifferentiated cells with high nuclear-cytoplasmic (NC) ratio, coarse chromatin, and scanty cytoplasm. Mitotic activity was seen (indicated by arrows) (hematoxylin and eosin staining; ×10 magnification).

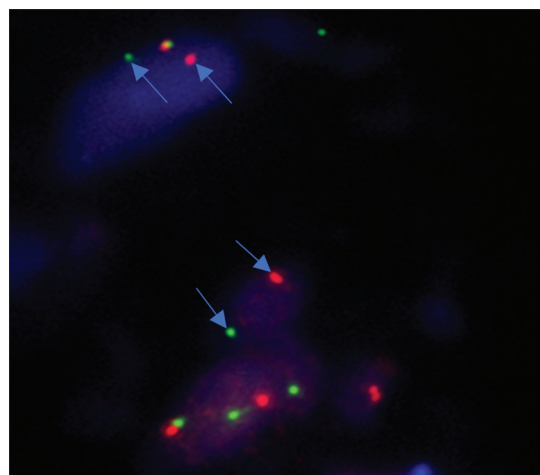


Figure 3. Fluorescent *in situ* hybridization performed using dual-color break-apart probes for *EWSR1* gene to show separate green (3' *EWSR1*) and red (5' *EWSR1*) signals which indicate *EWSR1* rearrangement (red-green) (×1000 magnification).

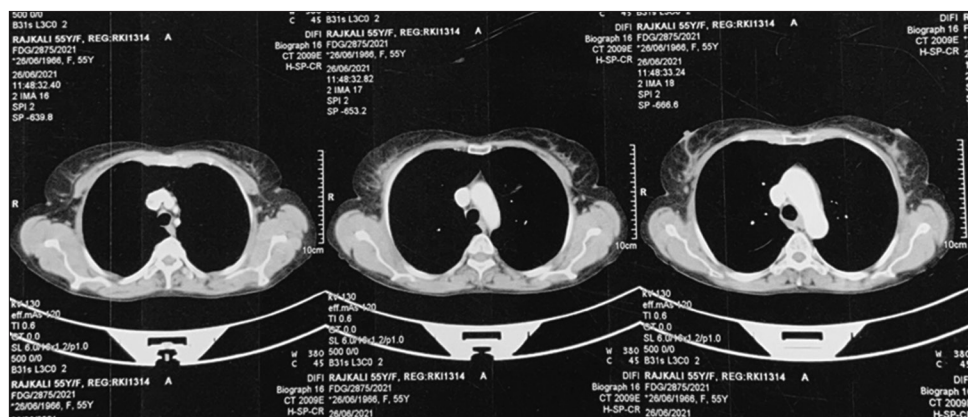

Figure 4. Post-excisional biopsy positron emission tomography-computed tomography (positron emission tomography-computed tomography) scan of thorax region showing normal scan with no evidence of residual tumor in the right breast.

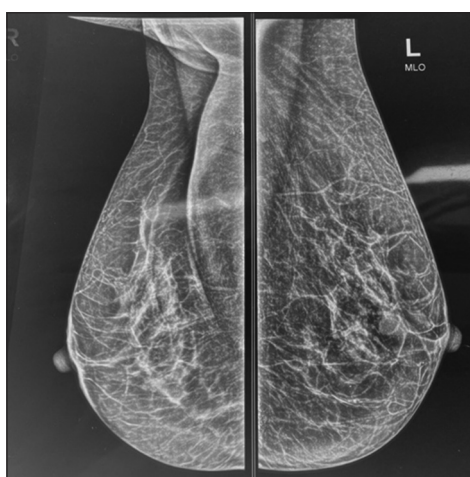

Figure 5. Post-excisional mammogram of bilateral breast (mediolateral view) with normal scan showing no architectural distortion or mass lesion.

adolescent and younger age group. Primary PNETs mainly affect the truncal and axial soft tissue, including the chest wall (Askin tumor), the extremities, and the paravertebral region^[8]. More than 85% of EWS is characterized by the presence of the typical translocation $t(11;22)(q24;q12)$. Immunophenotyping further establishes the diagnosis of EWS/PNET, which shows positivity for vimentin, Fli-1, and CD99 (MIC2)^[1]. Majority of patients with EWS/PNET belongs to the age group of 10 – 20 years. It has been reported in several studies on EWS in adult patients from Memorial Sloan Kettering Cancer Center and the Royal Marsden School that the patients had a median age of 24 – 27 years^[19]. However, the patient reported in this case was 55 years old. EWS presenting as a primary breast lesion in older age group is very rare and poses a diagnostic dilemma. Findings from ultrasonography and mammography may vary. Similar cases have been reported and were initially misdiagnosed as fibroadenoma, phyllodes tumor, and mammary carcinoma. This diagnostic dilemma may cause a delay in treatment. In our patient, a

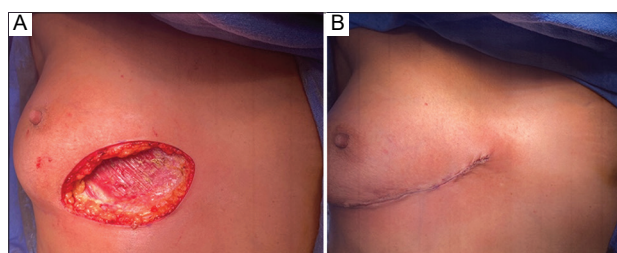


Figure 6. Intraoperative images of breast conservation surgery. (A) Defect created after wide local excision. (B) Good cosmesis after immediate closure of defect.

cystic mass with iso- to hyperechoic content was initially identified on ultrasonography and was misdiagnosed as cystic lesion and therefore considered benign. Excisional biopsy confirmed the diagnosis of small round cell tumor. Immunohistochemistry results further corroborated the diagnosis of EWS. However, the unusual site of EWS in the non-typical age groups poses a challenge to the timeliness of the diagnosis and hence the treatment.

EWS/PNET is an aggressive tumor with high incidence of local recurrence and distant metastasis. Multi-modality treatment including local control with R0 resection followed by adjuvant systemic treatment is advised. Systemic chemotherapy improves the 5-year survival rate in localized PNET from 10% to 65% by preventing micrometastasis^[20].

EWS/PNET of the breast is extremely rare. Sixteen cases of breast EWS have been reported thus far (**Table 1**) and had been managed by multi-modality treatment approach, including breast conservation surgery or mastectomy. Out of the 16 reported cases, three cases underwent mastectomy, followed by systemic chemotherapy in two cases. Seven cases underwent wide local excision or breast conservation surgery, three cases underwent systemic chemotherapy and one case received neoadjuvant chemotherapy. On follow-up, these patients remained disease-free. The remaining six cases received either chemotherapy alone or a combination of

Table 1. Summary of previously reported cases of breast Ewing's sarcoma

Case report	Age of patient (years)	Presentation	Size (cm)	Treatment
Tamura <i>et al.</i> ^[3]	47	Lump	2.1 × 1.8	Mastectomy
Maxwell <i>et al.</i> ^[4]	35	Lump	1.8	Lumpectomy + chemotherapy
da Silva <i>et al.</i> ^[5]	35	Lump	12 × 7.5	Chemotherapy + radiotherapy
Ko <i>et al.</i> ^[6]	36	Lump	2.5 × 2	Lumpectomy
Vindal and Kakkar ^[7]	26	Lump	3 × 2	Wide local excision + chemotherapy
Kwak <i>et al.</i> ^[8]	49	Axillary mass	-	Chemotherapy
Dhingra <i>et al.</i> ^[9]	26	Lump	3.5 × 3	Wide local excision
Sueb Wong <i>et al.</i> ^[10]	46	Lump	4	Radiotherapy
Majid <i>et al.</i> ^[11]	30	Lump	7 (right), 5 (left)	Chemotherapy
Mahajan <i>et al.</i> ^[12]	50	Lump	10 × 14	Mastectomy + chemotherapy
Ranade <i>et al.</i> ^[13]	61	Lump	6 × 6	Chemotherapy + radiotherapy
Meddeb <i>et al.</i> ^[14]	43	Lump	3	Breast conservation surgery + chemotherapy
Kim <i>et al.</i> ^[15]	35	Recurrent lump	2 × 2	Modified radical mastectomy + chemotherapy + radiotherapy
Popli <i>et al.</i> ^[16]	14	Lump	9.5 × 7 × 5	Wide local excision
Srivastava <i>et al.</i> ^[17]	25	Lump	11.6 × 9.2 × 6	Neoadjuvant chemotherapy + wide local excision
Ikhwan <i>et al.</i> ^[18]	33	Metastatic	-	Chemotherapy

chemotherapy and radiotherapy. As reported by Suebwong *et al.*^[10] and da Silva *et al.*^[5], the patients treated by chemotherapy combined with radiotherapy developed local and systemic relapse, further suggesting that surgery remains the cornerstone for local control. At present, no definite treatment of breast EWS has been reported. The role of radiotherapy in the treatment of PNET is unclear, but it can achieve local control if combined with surgery. If tumor-free margins are achievable after wide local excision or breast conservation surgery, then mastectomy can be avoided for management of EWS. Our reported case was managed with breast conservation surgery followed by adjuvant chemotherapy consisting of 18 weekly VAC regimen. During the 1-year follow-up, the patient remained disease-free. Our case showed that small tumors in patients with good breast volume can be managed with breast conservation surgery, and similar results can be achieved for mastectomy followed by adjuvant treatment.

4. Conclusion

The rarity of the primary breast EWS poses a diagnostic dilemma and hence the treatment. Local control with systemic therapy is the cornerstone of the treatment, in which breast conservation surgery is equivalent to mastectomy in local control in patient with good/average breast volume.

Acknowledgments

None.

Funding

None.

Conflict of interest

None.

Author contributions

Patient was treated by Dr. Jyoti Sharma, Dr. Ravi Venugopal and Dr. Ritu Thakur. All authors contributed to the case report conception and design. Histopathological analysis was undertaken by Dr. Adarsh Barwad. All authors were involved in revision of the manuscript. All authors read and approved the final manuscript.

Ethics approval and consent to participate

Informed consent was taken from patient, before her participation in study.

Consent for publication

Informed consent has been taken before publication.

Availability of data

Not applicable.

References

- Folpe AL, Goldblum JR, Rubin BP, et al., 2005, Morphologic and Immunophenotypic Diversity in Ewing Family Tumors: A Study of 66 Genetically Confirmed Cases. *Am J Surg Pathol*, 29:1025–33. DOI: 10.1097/01.pas.0000167056.13614.62
- Lamovec J, 1987, Breast Sarcoma. *Am J Surg Pathol*, 11:905–6.
- Tamura G, Sasou SI, Kudoh S, et al., 2007, Primitive Neuroectodermal Tumor of the Breast: Immunohistochemistry and Fluorescence *in situ* Hybridization. *Pathol Int*, 57:509–12. DOI: 10.1111/j.1440-1827.2007.02132.x
- Maxwell RW, Ghate SV, Bentley RC, et al., 2006, Primary Primitive Neuroectodermal Tumor of the Breast. *J Ultrasound Med*, 25:1331–3. DOI: 10.7863/jum.2006.25.10.1331
- Da Silva BB, Lopes-Costa PV, Pires CG, et al., 2008, Primitive Neuroectodermal Tumor of the Breast. *Eur J Obstet Gynecol Reprod Biol*, 137:248–9. DOI: 10.1016/j.ejogrb.2006.11.013
- Ko K, Kim EA, Lee ES, et al., 2009, Primary Primitive Neuroectodermal Tumor of the Breast: A Case Report. *Korean J Radiol*, 10:407–10. DOI: 10.3348/kjr.2009.10.4.407
- Vindal A, Kakar AK, 2010, Primary Primitive Neuroectodermal Tumor of the Breast. *J Clin Oncol*, 28:e453–5. DOI: 10.1200/JCO.2009.26.7542
- Kwak JY, Kim EK, You JK, et al., 2002, Metastasis of Primitive Neuroectodermal Tumor to the Breast. *J Clin Ultrasound*, 30:374–7. DOI: 10.1002/jcu.10076
- Dhingra KK, Gupta P, Saroha V, et al., 2010, Primary Primitive Neuroectodermal Tumor of the Breast: A Rare Entity. *Indian J Pathol Microbiol*, 53:880–882. DOI: 10.4103/0377-4929.72033
- Sueb Wong C, Wilairat P, Malee W, et al., 2012, Ewing's Sarcoma and Primitive Neuroectodermal Tumour (ES/PNET) Presenting as a Breast Mass. *Oncol Lett*, 4:67–70. DOI: 10.3892/ol.2012.698
- Majid N, Amrani M, Ghissassi I, et al., 2013, Bilateral Ewing Sarcoma/Primitive Neuroectodermal Tumor of the Breast: A Very Rare Entity and Review of the Literature. *Case Rep Oncol Med*, 2013:964568. DOI: 10.1155/2013/964568
- Mahajan M, Raju KV, Rehmani K, et al., 2014, Primitive Neuroectodermal Tumour of Breast-a Case Report. *Indian J Surg Oncol*, 5:89–91. DOI: 10.1007/s13193-014-0289-4
- Ranade M, Shah A, Desai SB, et al., 2020, A Curious Case of Ewing Sarcoma with Epithelial Differentiation, Presenting as a Breast Mass. *Breast J*, 26:2244–5. DOI: 10.1111/tbj.14045
- Meddeb S, Rhim MS, Kouira M, et al., 2014, Ewing's Sarcoma: An Uncommon Breast Tumor. *Clin Pract*, 4:659. DOI: 10.4081/cp.2014.659
- Kim YS, Lee KH, Choi SJ, et al., 2010, Extraskelatal Ewing's sarcoma of the Breast, Mimicking Cyst. *J Korean Surg Soc*, 79:411–4. DOI: 10.4174/jkss.2010.79.5.411
- Popli MB, Popli V, Bahl P, et al., 2009, Extraskelatal Ewing's Sarcoma of the Breast. *Eur J Radiol*, 70:e65–6. DOI: 10.1016/j.ejrex.2008.11.005
- Srivastava S, Arora J, Parakh A, et al., 2016, Primary Extraskelatal Ewing's Sarcoma/Primitive Neuroectodermal Tumor of Breast. *Indian J Radiol Imaging*, 26:226–30. DOI: 10.4103/0971-3026.184408
- Ikhwan SM, Kenneth VK, Seoparjoo A, et al., 2013, Primary Extraskelatal Ewing's Sarcoma/Primitive Neuroectodermal Tumour of Breast. *BMJ Case Rep*, 2013:bcr2013009584. DOI: 10.1136/bcr-2013-009584
- Chuthapisith S, Prasert W, Warnnissorn M, et al., 2012, Ewing's Sarcoma and Primitive Neuroectodermal Tumour (ES/PNET) Presenting as a Breast Mass. *Oncol Lett*, 4:67–70. DOI: 10.3892/ol.2012.698
- Paulussen M, Ahrens S, Dunst J, et al., 2001, Localized Ewing Tumor of Bone: Final Results of the Cooperative Ewing's Sarcoma Study CESS 86. *J Clin Oncol*, 19:1818–29. DOI: 10.1200/JCO.2001.19.6.1818

Publisher's note

Whoice Publishing remains neutral with regard to jurisdictional claims in published maps and institutional affiliations.